



# Total Hip Arthroplasty for Aseptic Osteonecrosis in Sickle Cell Patients at the Hospital General De Reference De Niamey / Niamey.

Mohamed ABDOUL WAHAB A<sup>1\*</sup>, Dalatou MH<sup>2</sup>, Garba IDE<sup>3</sup> and Seyni ISB<sup>2</sup>

<sup>1</sup>Orthopedic Traumatology Department, Niamey General Reference Hospital, Niger

<sup>2</sup>Orthopedic Traumatology Department, Lamordé Hospital, Niger

<sup>3</sup>Orthopedic Traumatology Department, Niamey National Hospital, Niger

**\*Corresponding author:** Dr. Abdoul Wahab A Mohamed, Assistant Professor at the Niamey Faculty of Health Sciences, orthopedic surgeon at the Niamey-Niger General Reference Hospital, Niger; Tel: 90245544; Email: medwahabe@gmail.com, <https://orcid.org/0000-0002-2509-2621>

## Research Article

Volume 8 Issue 2

Received Date: April 12, 2024

Published Date: May 22, 2024

DOI: 10.23880/jobd-16000262

## Abstract

**Introduction:** Aseptic osteonecrosis of the femoral head is one of the frequent bone sequelae of sickle cell disease. It is difficult and costly to treat. The aim of this study was to determine the complications and evaluate the functional results.

**Material and methods:** This was a retrospective monocentric study including total hip replacements in sickle cell subjects (March 2015 to May 2019), excluding patients with severe comorbidity. The mean follow-up was 12 months.

**Results:** During the study period, 17 patients with sickle cell disease underwent total hip arthroplasty for aseptic osteonecrosis of the femoral head. There were 10 women (58.82%) and 07 men (41.18%). The mean age of the patients, all sexes combined, at the time of surgery was 31 years. The distribution of the hemoglobinopathy phenotype was dominated by the SS homozygous form, accounting for 52.94% of patients. The mean preoperative PMA score was 8.41/18. Radiological classification by Ficat and Arlet showed that 82.35% of hips were stage 4 and 17.65% stage 3. Arthroplasty was performed via a posterolateral Moore approach under spinal anesthesia. Postoperative clinical re-evaluation showed marked improvement, with a mean postoperative PMA score of 17.17/18.

**Conclusion:** The functional and radiological results obtained over time make total hip arthroplasty the treatment of choice for osteonecrosis of the femoral head in sickle cell disease.

**Keywords:** Arthroplasty-Hip-Osseonecrosis; Aseptic-Sickle Cell Disease

**Abbreviations:** PMA: Postel Merle d'Aubigné Score.

## Introduction

Sickle cell anemia is an autosomal inherited hemoglobin disorder caused by the presence of abnormal Hb S replacing normal Hb A [1,2]. The condition affects around 50 million

people worldwide. It is widespread in sub-Saharan Africa, North America, the West Indies, Southern Europe, India and the Middle East [3]. The presence of Hb S is symptomatic in the homozygous SS or heterozygous SC and S beta thalassemia states. The heterozygous AS form is usually asymptomatic [4]. In some cases, the evolution of this hemoglobinopathy is dramatic, with osteoarticular damage, notably epiphyseal

osteonecrosis, necessitating arthroplasty in certain advanced and incapacitating forms. The aim of arthroplasty is to restore indolence, mobility and good joint function [5]. The aim of this study was to determine complications and evaluate functional results.

## Materials and Methods

We conducted a descriptive and analytical monocentric retrospective study over an 18-month period from March 2015 to September 2016 in the orthopedic traumatology department of the Niamey General Reference Hospital. A total of 17 patients were registered. Sickle cell patients were included, of both sexes and age greater than or equal to 20 years, who had undergone total hip arthroplasty for aseptic osteonecrosis of the femoral head during the study period and had a usable medical record. Non-sickle cell patients who had undergone total hip arthroplasty or sickle cell patients with severe comorbidity were not included. Data were collected using a pre-established data collection form and analyzed using SPSS software version 20. The statistical test used was Pearson's chi-square. A P value of < 0.05 is considered significant. Graphs were produced using Microsoft Excel 2016. Clinical, therapeutic and evolutionary variables were evaluated. The Postel Merle d'Aubigné Score (PMA) was used for functional assessment of patients. The mean follow-up period was 12 months.

## Results

During the study period, 17 sickle cell patients underwent total hip arthroplasty for aseptic osteonecrosis of the femoral head. There were 10 women (58.82%) and 07 men (41.18%). The sex ratio was 1.42 in favor of women. The distribution of patients by age showed a peak frequency in the 26-30 age bracket with 23.53%, and in the 31-35 age bracket with 29.42% of cases (Figure 1). The average age of patients of all sexes at the time of surgery was 31, with extremes of 19 and 46, and 70.59% of patients lived in urban areas.

The distribution of the hemoglobinopathy phenotype was dominated by the SS homozygous form, accounting for 52.94% of patients. AS heterozygosity was found in 29.41% of cases, and SC heterozygosity in 17.65% of patients (Figure 2). Involvement was bilateral in 47.06% of patients and unilateral in 52.94%. Clinically, pain was constant. Along with walking discomfort, it was the main reason for consultation. Hip condition prior to arthroplasty, assessed using the Postel Merle d'Aubigné clinical score, was impaired, with an overall PMA score of 9/18 or less in 64.71% of cases. The mean preoperative PMA score was 8.41/18. The radiological classification by Ficat and Arlet showed that 82.35% of hips were stage 4 and 17.65% stage 3. No cases of stage 1 or 2 were found (Figures 4 & 5).

Arthroplasty was performed via a posterolateral Moore approach under spinal anesthesia. Postoperative reassessment of the clinical score showed marked improvement. The postoperative PMA score was 18 (normal) in 47.06% of patients, 17 in 23.53% and 16 in 29.41%. The mean post-operative PMA score was 17.17/18. This improvement concerned all parameters: pain, mobility and gait.

The arthroplasty was complication-free in 94.11% of patients. One case of postoperative pulmonary embolism was recorded and managed. After a modest average follow-up of 1 year, prosthesis survival was 100%.

## Discussion

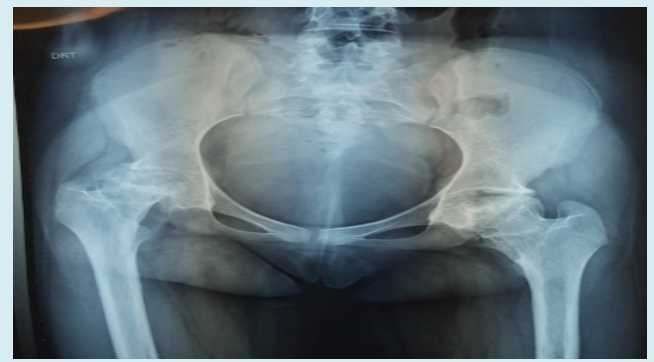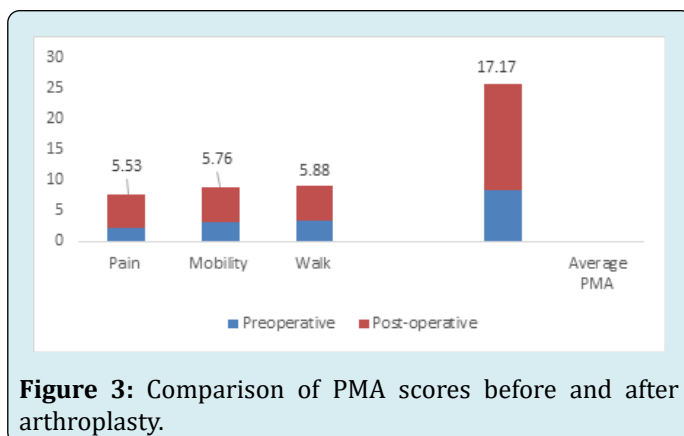
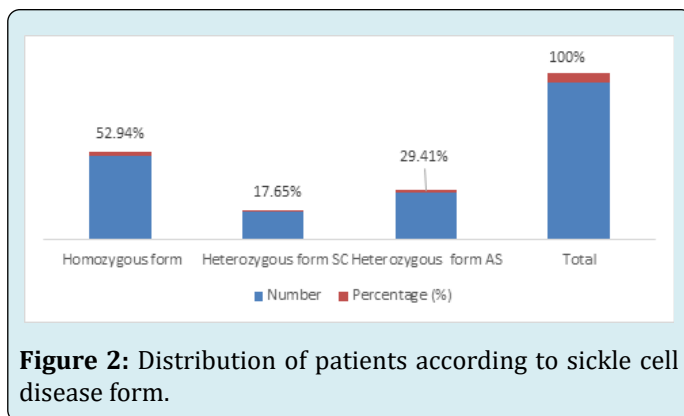
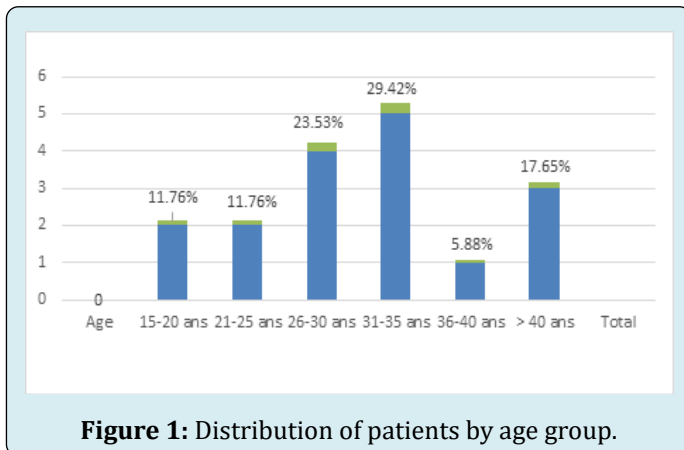
Aseptic osteonecrosis of the femoral head is one of the frequent bone sequelae of sickle cell disease [6,7]. Its exact incidence remains difficult to establish due to the small number of studies on the subject, despite the size of the population suffering from it [8]. In their series, Coulibaly Y, et al. [9] report a hospital frequency of 0.73%, and Diop S, et al. [10] a frequency of 9.2%.

In our study, we performed total hip arthroplasty in 17 sickle cell patients for aseptic osteonecrosis of the femoral head, with a female predominance of 58.82% and a mean age of 31 years. This female predominance is generally found throughout the literature [8,11] and could be explained by the large body mass in women [10]. The young age of our patients is consistent with most series [9,11]. Our patients were predominantly homozygous sickle cell SS (52.94%), with bilateral involvement in 47.06% of cases. These results are comparable to those of Mouhamed Zubair F, et al. [7]. As reported by other authors [3,7], pain and walking discomfort were the main reasons for consulting our patients, deteriorating their quality of life. The radiological classification of Ficat and Arlet showed that all hips were in stage III or IV. This could be explained by the fact that patients often consult us late, as the disease is insidious and the abrupt clinical onset often already corresponds to a relatively late stage of evolution, and conventional radiology always lags behind other diagnostic imaging methods [8,9,12]. The aim of treating aseptic osteonecrosis of the femoral head in sickle cell patients at these late stages was to restore as complete locomotor function as possible, in order to preserve the patient's socio-educational future [3,7]. A number of radical therapies have been proposed for this purpose, at this stage of evolution when conservative treatment is no longer an option [13]. The functional gain achieved over time makes total hip arthroplasty the treatment of choice [4,13]. Post-operative functional reassessment of our patients has shown convincing functional results as reported in the literature [14,15]. Prosthesis survival in our study at a mean follow-up

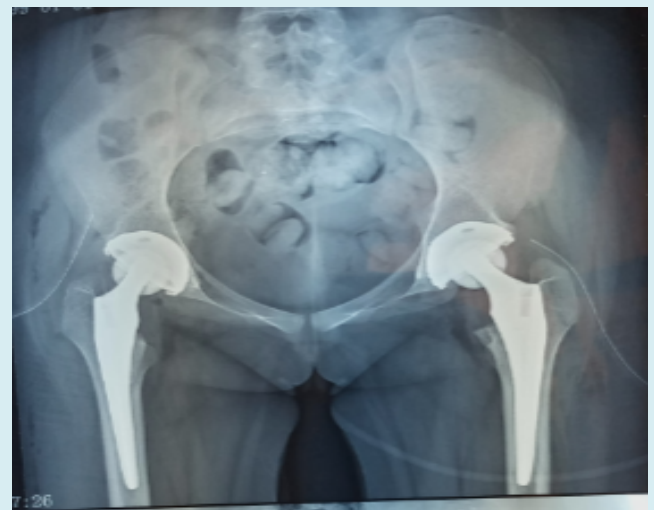of 1 year was 100%. Complications such as peri-prosthetic fracture, aseptic loosening and deep infection have been reported in other series [4,8,12,15] with sufficient follow-up.

## Conclusion

Osteonecrosis of the femoral head in sickle cell disease remains a frequent and serious lesion, as it impairs the patient's quality of life. It is difficult and costly to treat. The functional and radiological results of total arthroplasty appear conclusive. Correct follow-up of patients with sickle cell disease should prevent this disabling complication.



**Figure 4:** Preoperative pelvic Rx of a 20-year-old female patient with SS sickle cell disease who presented with bilateral ONTF.



**Figure 5:** Rx of the pelvis of the same patient after arthroplasty.

## References

1. Bachir D, Zemirline F, Niakate A, Galacteros F (2015) Sickle cell disease: the occupational physician, an essential relay in information and care. *Archives of Occupational Diseases and the Environment* 77(3) : 376.
2. Manzary M (2011) Total Hip Arthroplasty in Sickle Cell Disease. *Reconstructive review* 6(2).
3. Kpadonou G, Fioffi-Kpadonou E, Alagnidé E (2011) Problems of rehabilitation in patients with sickle cell disease in Cotonou, Benin. *Med Trop* 71(6): 558-561.
4. Sene M, Dansoko A, Ndiaye A (2009) Total hip arthroplasty after avascular necrosis due to sickle cell disease in Senegal: series of 48 replacements. *Med Trop* 69(6): 573-576.

5. Homawoo K, Bissang K, Songne B (1991) Sickle cell disease and osteonecrosis of the femoral head: Therapeutic considerations based on 38 cases. *Médecine d'Afrique Noire* 38 (7).
6. Mukisi Mukasa M, Manicom O, Alexis C (2009) Treatment of sickle cell disease's hip necrosis by core decompression: A prospective case-control study. *Orthop Traumatol Surg Res* 95(7): 498-504.
7. Mohamed Zubair F, Moji A, Karthik S (2019) Total hip arthroplasty in osteonecrosis secondary to sickle cell disease. *International Orthopaedics* 43(2): 293-298.
8. Benabdeslam A, Lahlou A, Elbardouni A (2014) Total hip arthroplasty (THA) in the aseptic osteonecrosis of the femoral head in sickle cell disease. *Elixir Human Physio* 68: 22243-22245.
9. Coulibaly Y, Coulibaly T, Maiga A (2009) Aseptic osteonecrosis of the femoral head in sickle cell patients: epidemiological and therapeutic aspects in the orthopaedic and traumatological surgery department. *Mali médical* 24(4): 43-46.
10. Diop S, Mokono S, Ndiaye M (2003) Homozygous sickle cell disease in patients above 20 years of follow-up of 108 patients in Dakar. *Rev Med Interne* 24(11): 711-715.
11. Faisal A (2004) Complications and Failures of Hip Replacement in Sickle Cell Disease. *Bahrain Medical Bulletin* 26(4): 1-8.
12. Hernigou P (2006) Non-traumatic osteonecrosis of the epiphyses in adults. *encyclopédie médico-chirurgicale appareil locomoteur* 14-028-A-10.
13. Atul F, Michael H, Craig L (2015) Surgical management of osteonecrosis of the femoral head in patients with sickle cell disease. *World Journal of Orthopedics* 6(10): 776-782.
14. Philippe H, Sebastien Z, Paolo F (2008) Total THA in adult osteonecrosis related to sickle cell disease. *Clin Orthop Relat Res* 466(2): 300-308.
15. Kinkpe CVA, Niane M, Porgo (2017) Total hip arthroplasty in patient with sickled cell trait SS: the cases of 14 Patients. *Journal of Orthopedics & Bone Disorders* 1(7): 000138.